

A Diagnostic Mistake, Treated with Shock Waves: Dabska Tumor

Paul Germán Terán Vela¹, Felipe Sebastián Criollo Palacios², Estefanía Anabel Lozada Tobar¹, Luis Eduardo Guzmán Freire³, Eloísa Abigael Nájera García²

Abstract

Papillary intralymphatic angioendothelioma (PILA) or Dabska tumor (DT) is a low-grade angiosarcoma. This vascular tumor usually has a higher incidence during childhood and occurs the most in the extremities and trunk. DT is locally aggressive, and no high metastatic potential is reported. We present a case of a 34-year-old female patient, treated with extracorporeal shock wave therapy (ESWT) for a misdiagnosis of left patellar tendinopathy. Due to the persistence and intensification of her symptoms, she is re-evaluated by Orthopedic Specialists. In magnetic resonance imaging studies, a mass was identified in the left external femoral condyle measuring approximately 10 mm with significant diffuse bone edema. Surgical resection was performed, and a PILA was identified by immunohistochemistry. In this case report, the complications of the use of focused ESWT and the histopathological characteristics of DT are discussed.

Keywords: Dabska tumor, Intralymphatic papillary angioendothelioma, Focused shock waves, Complications

Introduction

Papillary intralymphatic angioendothelioma or Dabska tumor (DT) is a diagnostic challenge as it is a rare pathology. Initially described in 1969 at the María Skoldowska-Curie Institute of Oncology [1], this low-grade angiosarcoma is a vascular tumor that usually develops in childhood. At present, there are only case series reports; Fanburg-Smith et al. [2] describe the case of 12 patients where the average age was 30 years, and most of their cases were at the level of glutes and thighs with a 50% incidence in these regions. According to the World Health Organization (WHO) [3], the most frequent sites of location are the extremities and the trunk.

DT is a slow-growing nodule that, when it reaches a size between 2 and 3 cm, presents clinical manifestations, with a high rate of local recurrence; however, metastases are rare [1]. Despite this, the WHO classifies DT as a locally aggressive tumor [3].

Microscopically it is characterized by the presence of anastomosing vascular channels,

some have papillary projections or tuft-shaped structures that simulate renal glomeruli [4]. The vascular channels, as well as the papillae, are lined by cuboidal endothelial cells and are often flanked by dense hyalinized areas containing large numbers of lymphocytes [5].

For proper management, it is necessary to make a correct diagnosis, surgical resection, characterization of the tumor, and finally follow-up management due to its higher probability of recurrence. Due to the small number of cases worldwide, the basic treatment is excision of the tumor, and follow-up examinations through imaging techniques are mandatory [6].

Case Report

A 34-year-old female patient consults complaining about pain in her left thigh, lasting approximately 2 months, with no apparent cause, no schedule or periodicity. She reports that the pain intensifies at night and in the early morning, sometimes, the pain is defined as electrical type. The patient was

initially managed in a Sports clinic where X-rays were evaluated (Fig. 1), then she was treated with focused shock waves for three sessions. There was no known protocol for the intensity or frequency of application. She also received in conjunction with extracorporeal shock wave therapy (ESWT) the following: Electrotherapy treatment, physical therapy, laser, magnetotherapy, and bicycle exercises. Pharmacologically, she was treated by the sports clinic with pregabalin 75 mg every day.

The patient states that the pain increased considerably in the weeks following the application of focused ESWT and presents to the orthopedic specialty consultation at our center. She reported intense pain throughout the thigh rated on the Visual Analog Pain Scale 8/10. A DN4 questionnaire was performed for neuropathic pain obtaining a value of 6/10. The pain was predominantly at night. She also reported intense pain during single-left leg support added to intense pain while performing full flexion and extension. In specific tests, there was no pain

¹Orthopaedic Surgeon, Orthopedic Specialties Center, Quito-Ecuador,

²NGC Diagnóstica, Orthopedic Oncology, Quito-Ecuador,

³Physician, Orthopedic Specialties Center, Quito-Ecuador.

Address of Correspondence

Dr. Paul Germán Terán Vela,

Orthopaedic Surgeon, Orthopedic Specialties Center, Quito-Ecuador.

E-mail: paulteranmd@gmail.com



Dr. Paul Germán Terán Vela



Dr. Felipe Sebastián Criollo Palacios



Dr. Estefanía Anabel Lozada Tobar



Dr. Luis Eduardo Guzmán Freire



Dr. Eloísa Abigael Nájera García

Submitted Date: 08 Apr 2024, Review Date: 26 May 2024, Accepted Date: 30 Jun 2024 & Published: 30 June 2024

Journal of Regenerative Science | Available on www.jrsonweb.com | DOI:10.13107/jrs.2024.v04.i01.125

© The Author(s). 2024 Open Access. This article is distributed under the terms of the Creative Commons Attribution 4.0 International License (<https://creativecommons.org/licenses/by-nc/4.0/>), which permits unrestricted use, distribution, and non-commercial reproduction in any medium, provided you give appropriate credit to the original author(s) and the source, provide a link to the Creative Commons license, and indicate if changes were made. The Creative Commons Public Domain Dedication waiver (<http://creativecommons.org/publicdomain/zero/1.0/>) applies to the data made available in this article, unless otherwise stated.

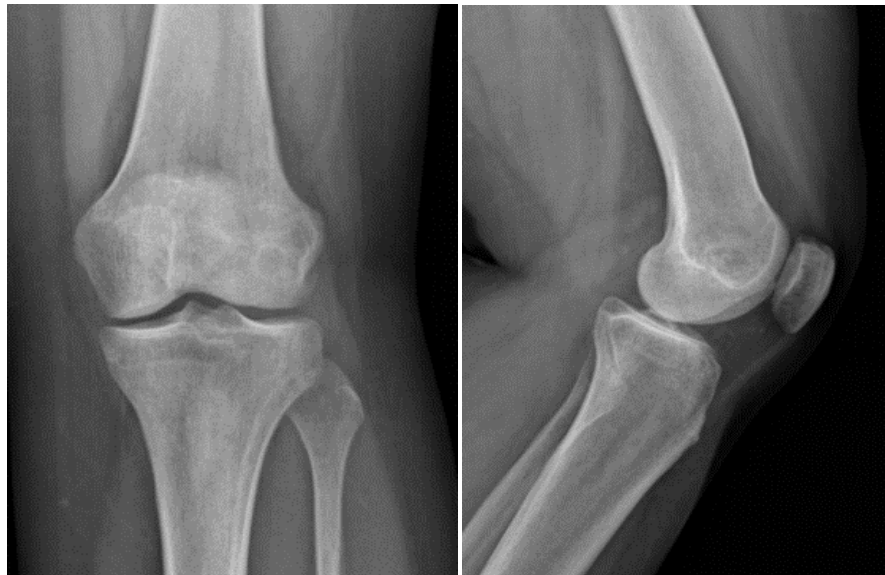

Figure 1: (a) AP and (b) lateral radiographs of the left knee with the presence of a radiolucent mass at the level of the lateral femoral condyle on the left side of approximately 5 mm diameter.

in the patellar tendon or for ligamentous or meniscus injuries.

In the magnetic resonance image (Fig. 2), extensive trabecular edema is observed in the femoral metaphysis and external femoral

condyle. A cystic formation is observed on the anterior edge of this condyle, with defined, sclerotic borders, measuring 10 mm of partially dense content, without adjacent periosteal reaction. The quadriceps tendon,

patellar tendon, internal collateral ligament, and insertion of the tendons that make up the pes anserinus show normal characteristics.

After these findings, surgical resection of the mass was performed through an extensive curettage divided into the following phases: (1) Curettage, (2) high-speed bone rimming, (3) electrofulguration, and (4) absolute alcohol exposure for 5 min. This process was repeated 3 times to amplify action margins in the bone tissue.

The sequential extended curettage led to an important bone defect cavity for which it was necessary to support the distal femur with a tricortical autograft from the iliac crest and an osteosynthesis plate (Fig. 3). To avoid cross-contamination, the tricortical bone block autograft from the iliac crest was initially taken.

The tissue obtained was histopathological and immunohistochemical analyzed revealing a CD31-positive tumor mass in endothelial cells of blood capillaries and in endothelial cells that form pseudopapillary structures in the capillary lumen, CK7 negative, CK20 negative, KI67 nuclear positivity in 1% of proliferating endothelial cells (Fig. 4). The tumor was reported as an intralymphatic papillary angioendothelioma (DT).

Discussion

Information on DT is limited, although its study began in 1969, its behavior, and its potential for malignancy are still unknown; however, its recurrence has been described and is also aggressive. Having been treated as patellar tendinopathy by a sports center, disease progression was possibly increased and exacerbated due to ESWT [7].

The patient initially underwent focused ESWT treatment without having an accurate diagnosis. When using this therapy, as described by Wang et al. [8], a biological effect is produced in the tissues, stimulating the production of angiogenic factors, which induce neovascularization. Specifically in bone, angiogenic activity includes increased production of nitric oxide synthase, vessel endothelial growth factor, bone morphogenetic protein-2, and proliferating cell nuclear antigen. In this way, the pain and symptoms were accentuated in the patient, since in the face of neovascularization caused by treatment with ESWT, the natural history of this DT was accelerated. Furthermore, the

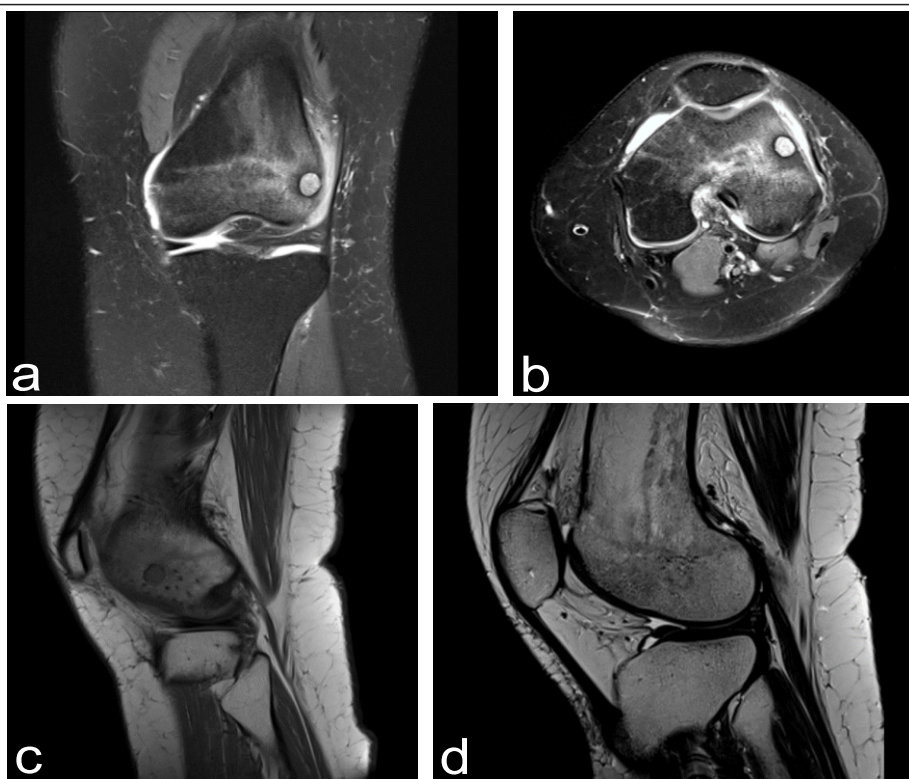

Figure 2: Magnetic resonance image of the left knee after the application of focused extracorporeal shockwave therapy (a) Coronal section (b) Axial section (c) Sagittal section T2 sequence (d) Sagittal section in T1 sequence.

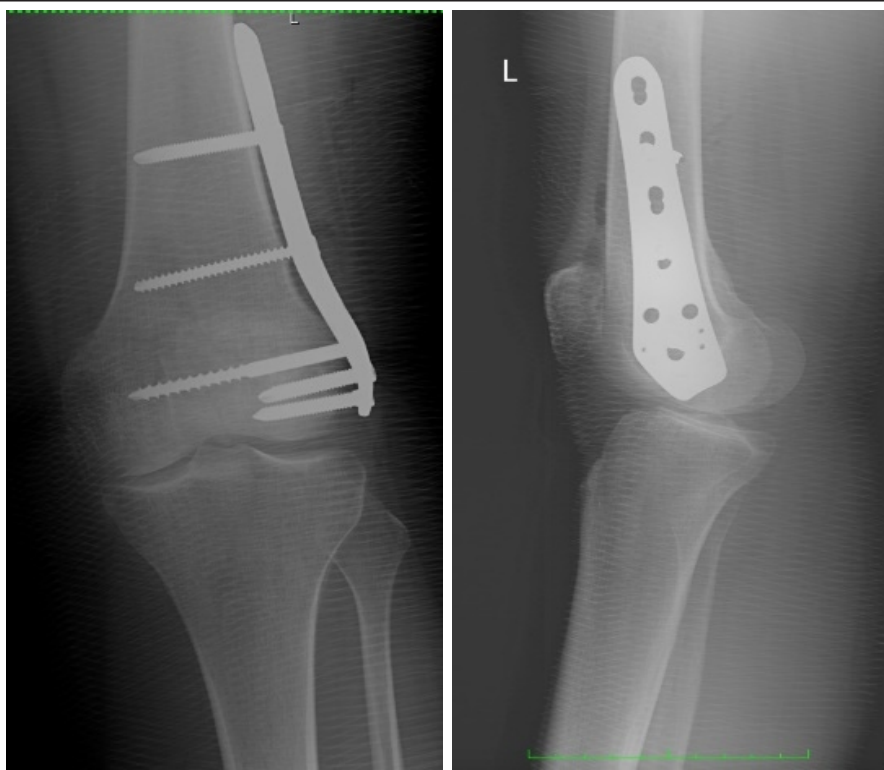

Figure 3: (a) AP and (b) lateral radiographs of the left distal femur after extensive curettage. The osteosynthesis plate is placed at the level of the lateral condyle.

production of anti-apoptotic factors such as the BCL-2 protein is increased as well as pro-apoptotic factors such as BAX and caspase 3

are downregulated [7,9]. It is essential that qualified specialized physicians not only analyze the case and

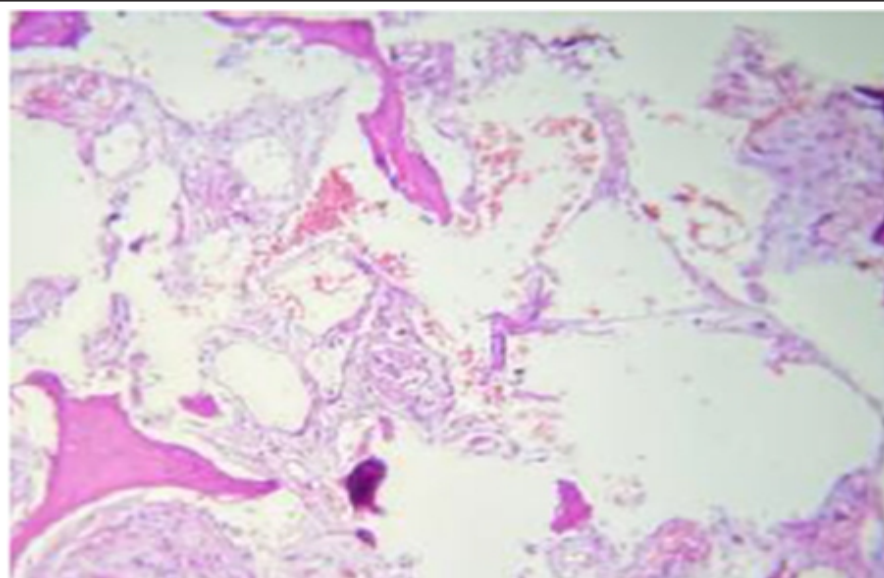


Figure 4: Microscopic image: Bone tissue with trabeculae that present fragmentation and degeneration due to a proliferation of blood capillaries into the connective tissue of the intertrabecular space. Flattened endothelium, without atypia. In occasional fields, the endothelium tends to form small lumens such as glands and nests of epithelioid cells, other capillaries present endothelial proliferation in the form of papillae that protrude into the lumen, in other areas, foci of old hemorrhage are observed.

reach a timely diagnostic criterion based on the orthopedic clinic. It is also important for the correct management of imaging examinations that must include all those necessary to have diagnostic safety and certainty. Similarly, it is indicated that the application of focused shock waves or radial pressure waves must be carried out by qualified and certified medical professionals to avoid possible errors such as those presented in the present case [7].

The international society for shockwave medical treatment [10] completely contraindicates the use of shock waves and radial pressure waves in tumors, due to the stimulation of angiogenic factors, which leads to the intensification of the symptoms resulting from the presence of the tumor mass.

According to Moya et al., there is a high incidence rate of erroneous diagnoses accompanied by underreporting of them. In this case, due to the error in the initial diagnosis, when applying ESWT on a tumor mass, a “biological repair process” was triggered, which generated an accentuation and exacerbation of the symptoms and findings related to the tumoral mass [7].

Evidence of the beneficial effects of ESWT can be seen between the 3rd and 6th month after the start of treatment [7]. In the case of our patient, the complications of the use of focused shock waves in a tumor area were evident almost immediately after their use and 2 months after treatment, the symptoms had greatly exacerbated.

In the event of a diagnostic failure, by performing a correct clinical evaluation and requesting the pertinent imaging studies, the tumor mass is identified. After the resection of the DT, in the subsequent controls, the patient reports significant improvement in her symptoms, now without any recurrence of the tumor mass.

Conclusion

Due to the low reported incidence of DT, the natural history of the tumor is not known nor is the clinical manifestations. However, this entity or other tumor masses must be present in patients with persistence and even intensification of their symptoms. Before starting treatment with ESWT, one must know the contraindications and, above all,

have diagnostic certainty to avoid the progression of tumoral pathologies. With

this case, we seek to corroborate the existing information on the adverse effects

of ESWT.

Declaration of patient consent: The authors certify that they have obtained all appropriate patient consent forms. In the form, the patient has given his consent for his images and other clinical information to be reported in the Journal. The patient understands that his name and initials will not be published, and due efforts will be made to conceal his identity, but anonymity cannot be guaranteed.

Conflicts of Interest: Nil. **Source of Support:** None.

References

- Schwartz RA, Dabski C, Da M. The dabska tumor: A thirty-year retrospect. *Dermatology* 2000;201:1-5.
- Fanburg-Smith JC, Michal M, Partanen TA, Alitalo K, Miettinen M. Papillary intralymphatic angioendothelioma (PILA). A report of twelve cases of a distinctive vascular tumor with phenotypic features of lymphatic vessels. *Am J Surg Pathol* 1999;23:1004-10.
- Fletcher CD, Krishnan K, Mertens UF. *Pathology and Genetics of Tumours of Soft Tissue and Bone*. Switzerland: WHO; 2002.
- Nakayama T, Nishino M, Takasu K, Hayakawa K, Toguchida J, Tanaka C. Endovascular papillary angioendothelioma (Dabska tumor) of bone. *Orthopedics* 2004;27:327-8.
- Bhatia A, Nada R, Kumar Y, Menon P. Dabska tumor (Endovascular papillary angioendothelioma) of testis: A case report with brief review of literature. *Diagn Pathol* 2006;1:12.
- Pozo-Kreiling JJ, Pena-Burgos EM, Ortiz-Cruz EJ, Cordero-García JM, Barrientos Ruiz I, Tapia-Viñe M, Peleteiro-Pensado M, Bernabéu-Taboada D. Primary intraosseous papillary intralymphatic angioendothelioma of the distal femoral epiphysis: a case report with literature review. *Skeletal Radiol*. 2024 Apr 15. doi: 10.1007/s00256-024-04674-8. Epub ahead of print. PMID: 38619614.
- Moya D, Ramón S, Guiloff L, Terán P, Eid J, Serrano E. Poor results and complications in the use of focused shockwaves and radial pressure waves in musculoskeletal pathology. *Rehabilitacion (Madr)* 2022;56:64-73.
- Wang CJ, Wang FS, Yang K. WANG Biological Mechanisms of ESWT. *ISMST Newsletter*; 2006. p. 5-11. Available from: http://www.shockwave.cc/e107_images/custom/sw-biological_mechanism_of_eswt.pdf [Last accessed on 2024 May 19].
- Moya D, Ramón S, Schaden W, Wang CJ, Guiloff L, Cheng JH. The role of extracorporeal shockwave treatment in musculoskeletal disorders. *J Bone Joint Surg* 2018;100:251-63.
- ISMST-International Society for Medical Shockwave Treatment ESWT Guidelines. Available from: <https://www.ismst.com>. Last accessed April 2024.

Conflict of Interest: NIL
Source of Support: NIL

How to Cite this Article

Terán Vela PG, Criollo Palacios FS, Lozada Tobar EA, Guzmán Freire LE, Nájera García EA. | A Diagnostic Mistake, Treated with Shock Waves: Dabska Tumor | *Journal of Regenerative Science* | Jan-Jun 2024; 4(1): 16-19.