Journal of Regenerative Science | 2022 Jan - Jun ; 2(1): 39-42

Shock Waves in Scaphoid Pseudarthrosis: A Case Series

Paul German Terán[1], Fidel Ernesto Cayon[1], Estefania Anabel Lozada[1], Alvaro Santiago Le Marie[2]

Abstract

Scaphoid fracture accounts for 60% of carpal fractures. The mechanism of fracture occurs after a fall with the hand extended, in pronation and radial or ulnar deviation in addition to the importance, they gain for their frequency; clinically, their problem lies in the high possibility of non-consolidation, due to the type of vascularization that it has, fractures located mainly in the waist and in the proximal pole are a high-risk factor. Most of the up-to-date papers available confirm a positive outcome of the use of focused extracorporeal shock wave therapy (ESWT-F) in pseudarthrosis. According to the literature, the success rate is between 50% and 91%. Complications when ESWT-F are performed by qualified personnel and following the standards established by international scientific organizations, are limited to petechiae and local hematomas having as a requirement, to be performed by trained personnel. This manuscript will discuss a series of cases treated in a certified center for the application of Focal Shock Waves between 2018 and 2021 to patients with scaphoid fracture with a diagnosis of Fracture Consolidation Delay and pseudarthrosis of scaphoids, which subjected to treatment with high-intensity focal shock waves under ultrasound guidance. We analyzed six male patients with an average age of 31.3 years who were treated with ESWT-F. About 33.3% were taken to osteosynthesis as initial management without achieving satisfactory bone consolidation; hence, ESWT-F was performed. About 0% complications were reported, bone consolidation occurred in 100% of patients on average of 6 weeks from the last session of ESWT-F. The results were clinically evaluated, where 100% of patients manifested a decrease in pain by an average of 75% at 2 weeks of the last session of ESWT-F and 100% at 12 weeks. In the imaging evaluation, the six patients (100%) showed signs of bone consolidation in the complete radiological assessment at 12 weeks and the Disabilities of the Arm, Shoulder, and Hand scale applied revealed improvement in their functional capacity.

Keywords: Scaphoid non-union, Delayed union, Extracorporeal shockwave therapy, Extracorporeal shock wave therapy, Pseudarthrosis, Disabilities of the arm, shoulder and hand

Introduction

The scaphoid is a very important bone in the biomechanics of the wrist, it fulfills the function of bridge between the two rows of the carpus [1] and provides significant stability to the mediocarpal joint [2, 3].

Scaphoid fracture is very common, accounting for 60% of carpal fractures [4]. The mechanism of fracture occurs after a fall with the hand extended, in pronation and radial or ulnar deviation [5,6], in addition to the importance, they gain for their frequency; clinically, their problem lies in the high possibility of non-consolidation, due to the type of vascularization it has, fractures located mainly in the waist and in the proximal pole are a high-risk factor.

Its irrigation comes from the dorsal carpal (70–80%) and superficial palmar (20–30%) branches of the radial artery, which, then, enters through the scaphoid's tubercle and provide a retrograde blood flow. Most of the proximal half of the scaphoid is covered by cartilage, leaving little surface area for vascular flow entry. Decreased bone blood flow can lead to poor fracture healing with delayed joining or non-joining, failed bone graft healing, and local avascular necrosis of the bone [7]. Due to its irrigation pattern, blood perfusion into the scaphoid may decrease after fracture and, as a result, impair bone consolidation; moreover, a variable percentage may go unnoticed due to lack of familiarity with the diagnosis, few symptoms and the absence of initial inflammatory changes, leading to late diagnoses [8,9]. Scaphoid fracture pseudarthrosis changes the mechanics of the wrist, which can lead to carpal collapse and secondary degenerative changes [9].

Surgical options are considered the gold standard in the treatment of lack of consolidation of the scaphoid, despite their considerable complexity and the risks of intraoperative complications [10].

[1]Department of Traumatology and Orthopedics, Orthopedic Specialties Center, Quito, Ecuador,
[2]Department of General and Laparoscopic Surgery, Universidad Internacional del Ecuador, Quito, Ecuador.

Address of Correspondence
Dr. Paul German Terán,
Department of Traumatology and Orthopedics, Orthopedic Specialties Center, Quito, Ecuador.
E-mail: paulteranmd@gmail.com


Dr. Paul German Terán


Dr. Fidel Ernesto Cayon


Dr. Estefania Anabel Lozada


Dr. Alvaro Santiago Le Marie

Submitted Date: 13 April 2022, Review Date: 18 April 2022, Accepted Date: 4 May 2022 & Published: 10 Jun2022

Figure 1: CEO Medical Records (a) Patient with scaphoid pseudarthrosis; (b) Patient treated with focused extracorporeal shock wave therapy with protocol described in this study.

Figure 2: CEO Medical Records (a) Patient with scaphoid pseudarthrosis; (b) Patient treated with focused extracorporeal shock wave therapy with protocol described in this study.

Figure 3: CEO Medical Records (a) Patient with scaphoid pseudarthrosis in the presence of stable osteosynthesis; (b) Patient treated with focused extracorporeal shock wave therapy with protocol described in this study.

Several efforts have been made to improve tissue regeneration and neovascularization in bones, including the use of growth factors and stem cells. These methods are highly expensive, non-affordable in most developing countries and are associated with ethical concerns, as autologous bone marrow grafting can cause complications at the donor site, such as infection, pain, and malformation; likewise, stem cell culture can lead to potentially dangerous cellular alterations for some patients. In addition, the efficacy of stem cell application in musculoskeletal regeneration remains questionable depending on the type of patient.

Non-surgical therapeutic options include ultrasound low-intensity pulses (LIPUS), as well as extracorporeal shock wave therapy (ESWT). LIPUS with intensities of 0.5–50 mW/cm2 is considered to stimulate bone healing. A recent study of 66 patients with fractures that did not heal appropriately, reported 67% overall success. However, in post-surgical scaphoid fractures, LIPUS treatment is not effective [2, 11].

An alternative treatment is the high-energy therapy with focal ESWT (ESWT-F) that offers a non-invasive therapeutic option for the lack of consolidation of the scaphoid [12].

Shock waves have a direct and indirect effect on tissues, which is called mechanotransduction. The absorbed shock waves produce a tensile force, this tensile force explains the direct effect. Shock waves also stimulate the formation of cavitation bubbles that expand, contract, collide, and form other bubbles in the treated tissue. The resulting energy also stimulates a biological response, this is the so-called indirect effect.

Mechanical studies support positive effect by means of increased bone mass, strength, angiogenesis by stimulation of vascular endothelial growth factor (VEGF), and increased osteogenic differentiation of mesenchymal stem cells by means of transforming growth factor b-1 (TGF) [13]. Bone morphogenic proteins play an important role in signaling ESWT activated cell proliferation and bone regeneration of segmental defects. It has been suggested that TGF-beta 1 and VEGF play a chemotactic and mitogenic role in the recruitment and differentiation of mesenchymal stem cells. Extracellular signal regulated kinase and p38 may influence the physical communication of ESWT stimulation in intracellular mitogenic responses. ESWT-F has been used for musculoskeletal disorders for over 30 years. Several studies have investigated the effects of shockwave therapy on healing fractures and articular cartilage in animal and human experiments.

The positive effect of shock wave on promoting bone healing was demonstrated in acute fractures and chronic pseudarthrosis in animal experiments. Fallnhauser et al. conducted a study with the aim of exploring the rate of bone consolidation and other outcome variables in patients with late consolidation of scaphoid fractures and pseudarthrosis of scaphoids treated with ESWT (0.41mJ/mm2, 4Hz, 4000 Focal impulses). The consolidation occurred in 71% of patients using ESWT, seven of the eight patients with immobilization and four of the five patients with scaphoid screws as primary therapy [12].

One of the first non-urological applications of ESWT treatment involved fractures that did not consolidate. Since the early 90s, the knowledge of the working mechanism has increased enormously. The purpose of this article is to provide, through peer-reviewed literature along with the cases presented in this study, that ESWT can be an effective, non-invasive alternative, and if the established norms are met at the interactional level we can avoid complications almost in its entirety also has less cost than the surgical treatment of scaphoid pseudarthrosis [14].

Patients and Methods

It is a descriptive and retrospective cohort study between 2018 and 2021. We included

Figure 4: CEO Medical Records. Ultrasound examination of scaphoid fracture under ultrasound vision.

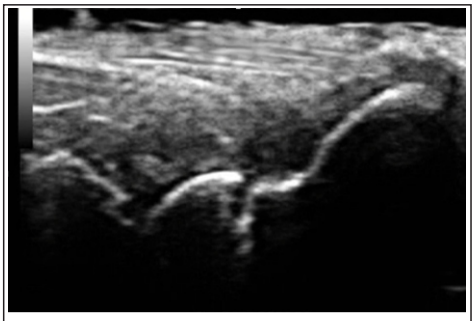

Figure 5: CEO Medical Records. Identification of focus of unconsolidated fracture of scaphoids under ultrasound vision.

Figure 6: CEO Medical Records. Application of focused extracorporeal shock wave therapy under indirect guidance.

Table 1: Patients with unconsolidated scaphoid fracture treated with Focales ESWT-CEO

Patient	Age	Time of Evolution Pseudarthrosis	ESWT-F Sessions	Comorbidities	Energy mJ/mm^2	Number of Waves used in each session	Osteosynthesis
Patient 1	35	5 months	3	No	0.25	2500 pulses	No
Patient 2	29	6 meses	4	Hypothyroidism (compensated)	0.35	2500 pulses	No
Patient 3	38	5 meses	3	No	0.4	2500 pulses	Yes
Patient 4	27	4 meses	3	No	0.4	2500 pulses	YES
Patient 5	29	5 meses	3	No	0.4	2500 pulses	No
Patient 6	31	6 meses	3	No	0.35	2500 pulses	No

Source: CEO Medical Records, ESWT-F: Focused extracorporeal shock wave therapy

six6 patients with carpal scaphoid fracture in consolidation delay or pseudarthrosis, who did not present decalage of more than 1 mm, who underwent high-intensity focal ESWT (ESWT-F) with a BTL 6000 equipment at the Center for Orthopedic Specialties (CEO) at Quito, Ecuador, guided with ultrasound using indirect visualization technique.

The treatment consisted of 3–5 sessions of focal ESWT, with 7 days interval, in each one the patient received 2500 pulses with a frequency of 3 Hz and an intensity between 0.25 and 0.40 mJ/mm2, as an adjuvant a wrist immobilizer with spigot was used for the first finger. The application of waves was carried out under indirect ultrasound guidance measuring evolution in each session.

Before ethical endorsement, the medical records were filtered from the CEO's files from ICD 10 code related to scaphoid fracture and lack or delay of consolidation. An orthopedic resident verified the information with the eligibility criteria, reviewed medical records and imaging reports, and recorded the data in a study collection format. Complications of ESWT, functional clinical outcomes, and imaging were evaluated.

Results

We identified six patients with unconsolidated scaphoid fracture treated with focal ESWT (Table 1), all of whom met the inclusion criteria. We analyzed six patients, all of them men, with an average age of 31.3 years. Only one patient (16.6%) had comorbidities and three were deficient in Vitamin D (50%). The trauma mechanism found in all cases was accident by fall with hand in extension (100%). Two patients underwent surgery.

About 100% of patients received focal ESWT according to the protocol described in this article, of which 100% presented adequate consolidation of scaphoids in an average of 6 weeks from the last session of ESWT-F. There were no complications during or after treatment.

The results were also clinically evaluated, where 100% of patients showed a decrease in pain by an average of 75% at 2 weeks of the last ESWT session and 100% at 12 weeks. In addition, the disabilities of the arm, shoulder, and hand (DASH) scale was applied at the beginning of treatment and 3 weeks after the last session of ESWT-F to measure functional capacity with values detailed in the corresponding table (Table 2).

In the imaging evaluation, the six patients (100%) presented signs of bone consolidation in the radiological assessment (Figs. 1 and 2).

Table 2: DASH scale applied to patients treated with ESWT-F for scaphoid pseudarthrosis in CEO

Patient	Initial DASH	DASH Post ESWT-F
Patient 1	31.66	4.16
Patient 2	30.86	6.66
Patient 3	23.33	0
Patient 4	29.16	4.16
Patient 5	31.66	5
Patient 6	24.16	0

Source: CEO Medical Records, DASH: Disabilities of the arm, shoulder, and hand, ESWT-F: Focused extracorporeal shock wave therapy

Discussion

Scaphoid fractures account for 60% of all carpal fractures. Its incidence has been increasing due to the increase in traffic accidents and sports-related injuries. Surgical procedures are considered the "gold standard" in the treatment of pseudarthrosis of the scaphoid. However, these are associated with possible complications and usually involve a considerable surgical effort.

High-energy ESWT-F is a non-invasive therapy method used in the treatment of pseudarthrosis. ESWT-F has been used for musculoskeletal disorders for more than 30 years. Several studies have investigated the effects of shockwave therapy on fracture healing and articular cartilage in animal and human experiments [15]. The positive effects of shock wave on the promotion of bone healing was demonstrated in both acute fractures and chronic pseudarthrosis in animal experiments [16, 17, 18].

In our study, the 3–5 sessions therapy of focal ESWT, 2500 pulses with a frequency of 3 Hz, and an intensity between 0.25 and 0.40 mJ, with 7 days of interval, in the six patients, led to a consolidation of the scaphoid of 100% in an average of 4 weeks from the last session of ESWT-F, which allows us to consider the therapy of high-energy extracorporeal shock focal waves as a valid treatment in this pathology.

As an important element of the treatment protocol with ESWT-F is the indirect visualization guide with ultrasound, because it allows us to identify the fracture site, as well as the depth of the bone defect, plan the application of ESWT-F, and evaluate the presence of bone callus and presence of blood vessels (see Figs. 3, 4, 5, 6) [19].

Conclusion

Focal ESWTs is a non-invasive therapeutic modality with efficacy, convenience, and safety. Focal ESWTs can replace surgery without surgical risks in many orthopedic disorders, including scaphoid pseudarthrosis. In our study, no complications were observed in patients treated with the indicated focal ESWT protocol. The presence of osteosynthesis material is not a contraindication to the use of Focal Shock Waves.

Systematic reviews and meta-analyses in scaphoid consolidation delays are used for ESWT-F to be included in the first line of the treatment in similar cases. Each patient whose comorbidities and characteristics of the fracture may alter the healing process should be analyzed.

Clinical Relevance

According to what has been reviewed in the literature on the optimal results of ESWT-F as a treatment in scaphoid pseudarthrosis, more research should be done in this field to increase the evidence and can be established with a treatment option of choice.

Declaration of patient consent: The authors certify that they have obtained all appropriate patient consent forms. In the form, the patient has given his consent for his images and other clinical information to be reported in the Journal. The patient understands that his name and initials will not be published, and due efforts will be made to conceal his identity, but anonymity cannot be guaranteed.

Conflicts of Interest: Nil. **Source of Support:** None.

References

1. Reigstad O, Thorkildsen R, Grimsgaard C, Melhuus K, Rokkum M. Examination and treatment of scaphoid fractures and pseudarthrosis. Tidsskr Nor Laegeforen 2015;135:1138-42.

2. Hernández PA, Arrieta DE, Lee Ruiz LS. Generalities of scaphoid fractures. Rev Med Sin 2020;5:e595.

3. Carreño F, Osma J. Orthopedics and Traumatology. Vol. 30. Amsterdam, Netherlands: Elsevier; 2016. p. 426-8. Available from: https://www.elsevier.es/es-revista-revista-colombiana-ortopedia-traumatologia-380-articulo-manguito-rotadores-epidemiologia-factores-riesgo-S0120884516300578. Last access on 2022.

4. Lee YM, Hwang ZO, Park JM, South YJ, Song SW. Double trapezia sign. Medicine (Baltimore) 2020;99:e22460.

5. Garcia AG. Fractures of the carpal scaphoid. Cir Cir 1953;21:199-206.

6. Valchanou VD, Michailov P. High energy shock waves in the treatment of delayed and nonunion of fractures. Int Orthop 1991;15:181-4.

7. Schleusser S, Song J, Stang FH, Mailaender P, Kraemer R, Kisch T. Blood flow in the scaphoid is improved by focused extracorporeal shock wave therapy. Clin Orthop Relat Res 2020;478:127-35.

8. Figures VJ, Azócar SC, Sanhueza FM, Cavalla AP, Liendo VR. Arthroscopic management of scaphoid pseudoarthrosis with hump deformity: Surgical technique and case series. Rev Chil Ortop Traumatol 2019;60:47-57.

9. Vázquez JM, Galindo JC. Delay of consolidation and pseudoarthrosis of the scaphoid. Medigr Artemis 2007;3:259-68.

10. Vergara EM. Vascularized bone graft for the scaphoid. Investig Orig 2011;59:281.

11. Knobloch K. Extracorporeal magnetotransduction therapy (EMTT) and high-energetic focused extracorporeal shockwave therapy (ESWT) as bone stimulation therapy for metacarpal non-union a case report. Handchir Mikrochir Plast Chir 2021;53:82-6.

12. Fallnhauser T, Wilhelm P, Priol A, Windhofer C. High-energy extracorporeal shock wave therapy in delayed healing of scaphoid fractures and non-unions: A retrospective analysis of the consolidation rate and factors relevant to therapy decisions. Handchir Microchir Plast Chir 2019;51:164-70.

13. Terán Vela P, Abarca WI, Martínez Asnalema D. Extracorporeal shock waves as a non-surgical treatment of delay of consolidation and non-bone union in diaphyseal fracture of the humerus associated with axonotmesis of the radial nerve, clinical case and literature review. Rev Ecu Med EUGENIO ESPEJO 2019;5:52-66.

14. Moya D, Ramón S, Guiloff L, Terán P, Eid J, Serrano E. Poor results and complications in the use of focal shock waves and radial pressure waves in musculoskeletal pathology. Rehabilitation 2021;4:13-18.

15. D'Agostino MC, Craig K, Tibalt E, Respizzi S. Shock wave as biological therapeutic tool: From mechanical stimulation to recovery and healing, through mechanotransduction. Int J Surg 2015;24:147-53.

16. Wang CJ, Cheng JH, Huang CC, Yip HK, Russo S. Extracorporeal shockwave therapy for avascular necrosis of femoral head. Int J Surg 2015;24:184-7.

17. Cheng JH, Wang CJ. Biological mechanism of shockwave in bone. Int J Surg 2015;24:143-6.

18. Wang CJ. Extracorporeal shockwave therapy in musculoskeletal disorders. J Orthop Surg Res 2012;7:11.

19. Balius R, Jimenez F. Interventional Ultrasound in Sports Traumatology. I. Madrid; 2015. p. 2-4.

Conflict of Interest: NIL
Source of Support: NIL

How to Cite this Article

Teran PG, Cayon FE, Lozada EA, Le Marie AS | Shock Waves in Scaphoid Pseudarthrosis: A Case Series. | Journal of Regenerative Science | Jan - Jun 2022; 2(1): 39-42.