Review Article
Journal of Regenerative Science | 2021 Jan- Jun; 2(1): 16-21

State-of-the-Art in Ultrasound-Guided Surgery: Concept, Planning, Instruments, Classifications, Indications, and Literature Review

Bernáldez Domínguez Pedro[1], Dallo Lazzarini Ignacio[1]

Abstract

Musculoskeletal ultrasound (MSK-U) and ultrasound-guided interventionism have had significant development and use in clinical practice in recent decades, including minimally invasive surgical procedures assisted by ultrasound. In the current literature, there is no consensus on the terminology of these procedures, with several terms used such as ultrasound-assisted surgery, ultrasound-guided surgery (UGS) or echo-guided surgery, sonosurgery, percutaneous ultrasound-guided procedures, and ultra-minimally invasive UGS. The MSK-U allows us to diagnose musculoskeletal injuries, but it is also a handy tool to assist us when performing different therapies on the tissues. They are procedures that require a good learning curve but that, once achieved, will allow us to develop other techniques depending on the type of pathology, obtaining good clinical results and in many cases avoiding having to open the focus or expand the surgical wound, with the advantages that this supposes. Therefore, UGS allows us to locate the exact site of the injury, understand the dynamics of the pathology; it does not need to open a wide surgical field, sometimes we will not put stitches or staples, and it can be combined with arthroscopic or endoscopic procedures (Ultrasound and Arthroscopic-guided Surgery). In this article, we describe the concept of UGS, its planning, the necessary instruments, the different indications, and a current concept review on the subject.

Keywords: Ultrasound-guided surgery, ultrasound-guided interventionism, ultrasound-assisted surgery, sonosurgery, ultrasound-arthroscopic surgery.

Introduction

With the enormous implantation of the musculoskeletal ultrasound (MSK-U) in clinical practice in recent decades and the significant development of ultrasound-guided interventionism (UGI), it is not surprising that minimally invasive surgical procedures assisted by ultrasounds are also increasing [1]. There is no consensus in the literature on how to nominate these procedures. Several terms are used, such as surgery assisted by ultrasounds or ultrasound-guided surgery (UGS), ultrasound-assisted surgery (UAS), sonosurgery, and percutaneous release guided by ultrasound, ultra-minimally invasive surgery guided by ultrasound. Likewise, isolated articles are published on a specific technique, without reviews or books that fully encompass all these new techniques and trends among various orthopedic surgeons. At present, its use is very limited in daily care practice and only carried out by some surgeons with or without the help of other medical colleagues' experts in ultrasounds. We believe that these techniques can be developed in the future given the advantages and benefits, with few risks or complications. The MSK-U not only allows us to diagnose injuries to the musculoskeletal system, but it is a fantastic tool to assist us when performing different therapies in the tissues. In 2017, we described the different indications for ultrasound-guided therapies, including ultrasound-guided Infiltration, percutaneous needle tenotomy, intracapsular hydrodelineation, hydrodissection, high volume injection, and percutaneous needle scraping [1]. Within UGI, we can incorporate the UGS.

This review aims to present the concept of UGS, how we perform it, and its advantages and disadvantages; we also present and classify its main indications, complications, ending with a bibliographic update. It would be very interesting to reach a consensus on the terminology used by the scientific community.

Background

At the beginning of the 21st century, radiologists mainly performed ultrasound-guided musculoskeletal interventions; courses dedicated to MSK-U emphasizing these procedures were scarce. The peer-reviewed literature contained a few articles focused on UGI [2]. A decade later, UGI in the US and Europe began to be performed by radiologists and sports doctors, rheumatologists, anesthesiologists, rehabilitators, orthopedic surgeons, family doctors, podiatrists, and other specialists [3]. UGI training is becoming more and more integrated thanks to the multiple courses, including workshops, masters, and training programs for residents. Furthermore, it is

[1]Department of Orthopaedic Surgery and Sports Medicine, SportMe Medical Center, Unit of Biological Therapies and Ultrasounds, Seville, Spain.

Address of Correspondence
Dr. Bernáldez Domínguez Pedro, Md. PhD.,
Tabladilla, 2, 41013, Seville, Spain.
E-mail: pedrobernaldez@gmail.com


Dr. Bernáldez Domínguez Pedro


Dr. Dallo Lazzarini Ignacio

Submitted Date: 16 Jan 2022, Review Date: 5 Feb 2022, Accepted Date: 11 Feb 2022 & Published: 10 June 2022

Figure 1: Disposition in the operating room performing an ultrasound-guide surgery.

Figure 2: Image showing triangulation during a knee ultrasound-guide surgery, using an arthroscope, ultrasound and motorized synovectomy.

Figure 3: Post-operative image of a ultrasound-guide surgery, where the mini-insition can be observed in the proximal 1/3 of the left leg and a distal bruise.

Table 1: Some specialties that perform ultrasound-guided interventionism (UGI)

Urology: Puncture and evacuation of renal cysts, biopsies, prostate cancer treatment
Gynecology: Removal of ultrasound-guided radiofrequency fibroids
General Surgery: Ultrasound-guided drainage of abdominal collections.
Anesthesiology: Ultrasound-guided loco-regional blocks, treatment of chronic pain
Traumatology and Orthopedics: Ultrasound or Arthroscopic-guided Surgery
Radiologists: Highlighting some national (Spain) units with extensive experience at UGI

necessary to highlight the exponential increase in articles related to UGI, making it increasingly difficult to keep up to date in this broad field. On the other hand, the use of IGI in other medical specialties is more than implemented years ago [4], highlighting some such as urology to perform puncture and evacuation of kidney cysts, taking biopsies, and treatment of prostate cancer. In gynecology, for the removal of myomas by ultrasound-guided radiofrequency. General surgery, drainage of ultrasound-guided abdominal collections. Anesthesiology, ultrasound-guided loco-regional blocks, chronic pain treatment, and radiologists highlight some national units with significant experience in UGI in Spain. (Table 1).

Concept

We opted for the term UGS for our part. We defined it as: That surgery in which we help ourselves at some point of the MSK-U as a means of vision and that facilitates its development, both in percutaneous, open or arthroscopic surgery, planning the approach, as well as to confirm an injury or its resolution [5] (Fig. 1).

Planning

Undoubtedly, these procedures require a good learning curve because we cannot forget that we perform a surgical procedure; ultrasounds are only the means, the end being surgery. But once achieved, it will allow us to develop different techniques in the same operating room. That is why this indication should not be trivialized. It will always be necessary to provide timely informed consent and respect all the aseptic measures required by a surgical intervention both of the surgical field and the probe. The key to this procedure is proper planning, locating the exact site of the injury by ultrasound, understanding the dynamics of the pathology, using adequate instruments and safe tools [4, 5].

The ideal is between two doctors, one who carries the probe and the other who performs the surgical procedure. In any case, it is essential to have the precise knowledge to triangulate correctly with both hands, if a single physician does it, as well as to have adequate instruments and a trained team (Fig. 2).

Advantages of the UGS

The advantages of UGS are several since it is a harmless, minimally invasive technique, and generally, with a painless postoperative period or with controlled pain, it is also relatively inexpensive (Table 2).

Disadvantages of the UGS

It is an operator-dependent technique requiring a particular skill when triangulating and performing the therapeutic act; it has a learning curve that presents specific

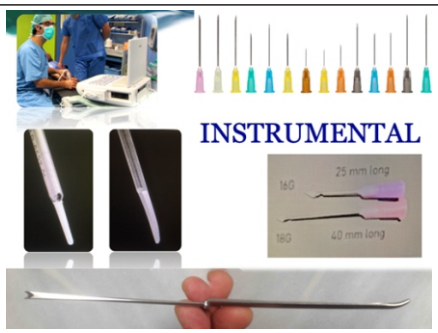

Figure 4: Instruments necessary to correctly perform an ultrasound-guide surgery.

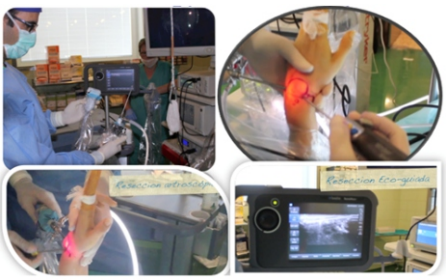

Figure 5: Image showing a ultrasound-guide surgery combining arthroscopy and ultrasound-guided resection of an arthrosinovial cyst of the wrist.

Figure 6: Percutaneous ultrasound-guided tenotomy for the treatment of lateral epicondylitis of the elbow.

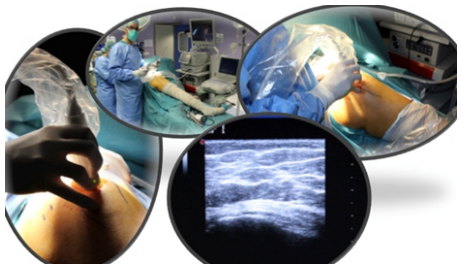

Figure 7: Intraoperative image of a ultrasound-guide surgery for the treatment of chronic trochanteric bursitis.

Figure 8: Image of a ultrasound-guide surgery for the treatment of chronic patellar tendon disease using ultrasound and arthroscopy at the same time.

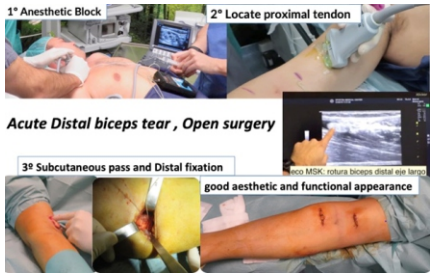

Figure 9: Triple application of ultrasound in a ultrasound-guide surgery for the re anchoring of an acute rupture of the distal biceps.

difficulties. Still, it is known that orthopedic surgeons are learned relatively easily and quickly due to their surgical training. Complications include the possibility of infection in the case of not respecting the minimum aseptic measures. In our experience, the percentage is below 3%. It is not superior to open surgery (classic) or arthroscopic techniques.

On the other hand, we must take precautions to avoid a neurovascular injury, for this it is essential to know the anatomy well and locate said structures, keeping them away from the surgical field, as well as avoiding hematomas or effusions (Fig. 3), that is why we always place a compression bandage the 1st days after UGS.

UGS Instruments

It is minimal, just an ultrasound with a high-frequency linear probe or warped (convex) for deeper structures; gloves, gel, needles of different sizes and lengths, different scalpels, and some more specific instruments (hooks, probes, and protectors). This instrument is under development and must continue to improve (Fig. 4 and Table 3). Proper positioning of the doctor is crucial, respecting ergonomics to avoid injuries, working comfortably, in a stable environment, and maximum asepsis.

Indications and Classification of the UGS (Table 4)

We start from the base of adequate knowledge both in MSK-U, surgical techniques, and UGS techniques. We must have an ultrasound machine in the operating room and all the basic aseptic measures. We can perform UGS in soft tissue pathologies such as Ganglions, hematomas, cysts, bursitis, tendinosis, fasciitis, capsulitis, spring fingers, nerve entrapments, calcifications, loose bodies, and osteophytes. There are also indications for UGS in combination with arthroscopic procedures, such as treating popliteal cysts and reducing post-operative pain [6].

Classification of the UGS

In our team, we classify UGS in three groups.

Closed (percutaneous) surgeries

Closed surgeries of the upper extremities

- Shoulder: Bicipital tenosynovitis
- Elbow: Epicondylitis and Epitrocleitis
- Forearm: Chronic Compartmental Syndromes
- Hand: Spring fingers, Dupuytren's disease, Carpal Tunnel Syndrome (Ultraminimally-invasive Surgery), and Tumors.

Closed surgeries of the lower extremities

- Trochanteric bursitis, Snapping hip, Morrel-Lavalle drainage
- Iliotibial Band Syndrome
- Percutaneous tenotomy
- Tendon lengthening (Achilles and hamstrings)
- Tendon sutures (Achilles)
- Evacuating clotted hematomas
- Fasciotomy of the medial calf muscles or plantar fascia
- Leg: Chronic Compartmental Syndromes
- Calcifications, tumors, or loose bodies.

Closed spinal surgeries

Ultrasound and arthroscopic-guided surgeries

- Ganglions
- Bursitis
- Tendinosis
- Tendon tears.

Open surgeries

- Chronic tendinopathies
- Calcifications
- Foreign bodies and free bodies
- Tumors.

At present, our team has carried out 80 UGSs (2014-2021) distributed by different joints. We have even been able to operate on the same patient with the same pathology, with open techniques on one leg and UGS on the other, years later. Likewise, we have combined a classic arthroscopic procedure such as ACL repair and UGS to perform exostoses in the hip in the same surgery.

Indications of the UGS

Our main indications are tendons, nerves, fasciae, cysts, and bursae, and highlighting the following pathologies according to their

Table 2: Advantages of the ultrasound-guided surgery
No hospital admission required
Does not emit ionizing radiation (health personnel and patients)
The technique is dynamic and allows us to mobilize the joints to see the result
Localizethe lesion with precisionas well as neurovascular structures
Low cost compared to open surgery (optimization of health expenditure)
Fast recovery
Better cosmetics (mini approaches)

location.

• Hand and wrist surgery

o Carpal Tunnel Syndrome [7, 8, 9, 10, 11]

o Treatment of the spring finger (ultrasound-guided pollectomy) [12]

o The assistance of arthroscopic surgery of wrist ganglions [13] (Fig. 5)

o De Quervain's tenosynovitis [14]

o Dupuytren's Disease: Ultra minimally-invasive surgery [15].

• Tendon and fascia surgery

o Patellar Tendinosis [16, 17]

o Achilles Tendinosis [18, 19]

o Percutaneous Achilles lengthening [20]

o Percutaneous Achilles suture [21, 22, 23, 24]

o Plantar fasciitis [25]

o Epicondylitis [26, 27, 28] (Fig. 6)

o Bicipital tenotomy [29]

o Iliotibial band Syndrome [5]

o Knee ligaments [30]

o Section of the coracoacromial ligament [31]

o Compartmental syndromes [32].

• Surgery on cysts and bursas

o Trochanteritis (gluteus medius and minor tendinosis)

o Bursitis: Knee, Shoulder, Elbow, Trochanteric bursitis (Fig. 7)

o Snapping hip [33].

• Surgery on calcifications and tumors.

o Location of calcifications before their excision (shoulder, elbow, knee, and hip).

• Locate loose or foreign bodies

o On neoformed cavities

o Locate tendon ruptures before their re-anchoring or suture [34].

• UGS on fractures

o Placement of external fixation (EF) [35].

Discussion

Discussion

In the current literature, there are more than 6000 articles indexed with the search "UGS," and 2600 with "UAS" but after its in-depth analysis, we observe that most are anesthesiology studies related to nerve blocks guided by ultrasound to perform all types of surgeries: Spine, thyroid, abdominal, plastic, urology, vascular, neurosurgery or traumatology, both in humans and animals [36]. We have seen the widespread use of ultrasound among veterinarians [37]. Still, very few use ultrasound to facilitate or assist surgery on the locomotor system, which does not adhere to the concept that we are talking about in this article [38]. On the other hand, with the term "Sonosurgery," we found only nine indexed articles, five for oral surgery, one breast surgery, one veterinary surgery, and only two for orthopedic surgery. The one that interests us is the article by Pilecki et al. [34], which incorporated this term in 2012, justifying the use of ultrasound for some surgical procedures as internal fixation of some fractures or the location of loose bodies for their subsequent extraction. The curious thing about this author is that he published a new article 2 years later, expanding the previous work with a new approach and adding indications. Still, he stops using the term "Sonosurgery" for UGS [39].

Since then, we have not observed any publication in PubMed with the same term. Our workgroup does not use it either since ultrasound does not perform any therapeutic act "as if it were a laser, a shock wave, or electrophoresis." Some patients ask us what effect ultrasound produces on their injury, explaining that it is only a means to assist in the development of surgery. For this reason, we prefer to use the term UGS. We explained these concepts in detail at a recent conference at the TOBI 2021 symposium [5]. Finnof et al. [40] highlight the importance of using specific instruments to be able to perform these ultrasound-guided techniques safely and with minimal morbidities, such as the release of the A1 pulley in hand and the release of the carpal tunnel with specific instruments, curved scalpels, retrograde knife, and endoscopic scissors. Use arthroscopic equipment or specially designed devices to perform tenotomy/fasciotomy that cut and debride damaged tissue. One of the most relevant aspects of UGS is to determine the exact approach path to avoid damaging neurovascular structures. It is essential to visualize and monitor the blood vessels and nerve structures (honeycomb pattern). This detail will prevent a high percentage of

Table 3: Material needed to perform a UGS
High-frequency linear probe
Different types of scalpels and needles
Accessory instruments
Gloves, gel, sterile antiseptic
In case of combining,it with arthroscopy: Camera, vaporizer, and synoviotome

Table 4: Indications of the UGS
Tendinopathies: Patellar (Fig. 8), quadricipital, Achilles, Biceps, etc.
Assistance to tendon ruptures: Distal biceps (Fig. 9),Achilles
Tendon lengthening and fascia: Medial calf, Achilles, iliotibial band, compartment syndromes
Cordectomies: Dupuytren's disease
Tumors, spring fingers
Cysts, ganglions
Canalicular Syndromes: Carpal tunnel syndrome, ulnar tunnel, tarsal sinus syndrome, and Morton's neuroma
Foreign bodies
Bruises, Osteoscopy
Bursitis and calcifying tendonitis
Knee ligaments
Assist in external fixation of fractures

morbidity in conventional surgeries [32, 38]. We use it in pathologies as diverse as in ultrasound-guided fasciotomy of chronic compartment stress syndromes of both the leg - locating the peroneal nerve superficial, as in the forearm -finding the radial, median and ulnar nerves, or in the pyramidal tenotomy in deep gluteal syndrome, and locating the inferior gluteal artery. On the other hand, performing a UGS does not imply doing the entire procedure using the probe. This has to be an aid to locate the precise point and then complete the surgical gesture comfortably, for example, passing a – hyperechogenic - suture through a tendon (hiccup), checking later that everything is correct.

The use of metallic instruments (scalpel, hooks, needles, and synoviotomes) produces a hyperechoic image that contrasts with muscle tissue (hypoechoic) that allows it to be easily identified and oriented. Of all the ultrasound-guided surgical techniques highlighted in the literature, we have organized them into three differentiated groups:

Release surgeries

Nerve decompression surgeries include carpal tunnel syndrome, lengthening: Medial calf muscle of the leg fasciotomy, tenotomies of the epicondyle, bicipital or Achilles tendons.

Resection surgeries

Osteophytes, foreign bodies, loose bodies, debride bruises, and effusions.

Repair surgeries

Tendon, ligament sutures.

Among the complications of UGS, three stand out above all [32]. (1) Infections: If we do not take the appropriate aseptic measures, (2) neurovascular injuries: despite controlling these structures, it is possible that by introducing a specific instrument, we can damage them by having a smaller field of vision, and (3) incomplete procedures: For this same reason, not having an open and well exposed surgical field, we may not fully complete the resolution of the pathology, for example, complete removal of calcifications, exostoses, fascia opening, or tendon release. Likely, many "traditional" surgical procedures will gradually become ultrasound-guided processes, which can be performed both in the operating room and in the office by qualified professionals, with a decrease in healthcare costs [40]. In addition, they may be combined with regenerative biological therapies [41, 42].

The fundamental tool is the use of the MSK-U, which stands out for being non-invasive, safe, does not emit radiation, and, if we take the appropriate aseptic measures, we know the anatomy, and we place a compression bandage at the end of the procedure, the rate of complications is minimal, and the degree of patient satisfaction is very high [5, 43].

Finally, this article does not intend to dogmatize or make the surgeon choose between using the conventional (classical) technique versus UGS (modern). But suppose, we highlight how ultrasounds have proven to be very useful in the office when diagnosing and even treating pathologies with UGI. In that case, it can also be helpful in the operating room when we perform any of the specific procedures mentioned previously in this manuscript.

Conclusion

Under the term UGS, we include that surgery in which we use ultrasound as a diagnostic method at some point, which can help us in its development, both in percutaneous, open or arthroscopic surgery. We can confirm an injury or the resolution of it. They are procedures that require a good learning curve but that, once achieved, will allow us to develop different techniques obtaining good clinical results and, in many cases avoiding having to open surgeries. It should not surprise us to have an ultrasound machine in the operating room or minor surgery room. Therefore, UGS allows us to locate the exact site of the injury, understand the dynamics of the pathology, and it does not need to open a wide surgical field; sometimes, we will not put stitches or staples. We need to continue evaluating these techniques with prospective, randomized, and controlled studies to create a solid evidence-based basis.

Declaration of patient consent: The authors certify that they have obtained all appropriate patient consent forms. In the form, the patient has given his consent for his images and other clinical information to be reported in the Journal. The patient understands that his name and initials will not be published, and due efforts will be made to conceal his identity, but anonymity cannot be guaranteed.

Conflicts of Interest: Nil. **Source of Support:** None.

References

1. Domínguez B. The ultrasound: The stethoscope of the Traumatologist: Diagnostic and therapeutic utility. Rev Traum Ort 2017;34:17-26.

2. Vo JN, Hoffer Fa, Shaw DW. Pediatric image-guided nonvascular musculoskeletal interventions. Tech Vasc Interv Radiol 2010;13:214-21.

3. Sconfienza LM, Adriaensen M, Albano D, Alcala-Galiano A, Allen G, Gómez MB, et al. Clinical indications for image-guided interventional procedures in the musculoskeletal system: A Delphi-based consensus paper from the European society of musculoskeletal radiology (ESSR)-part V, knee. Eur Radiol 2022;32(3):1438-1447.???:???.

4. Dietrich CF, Goudie A, Chiorean L, Cui XW, Gilja OH, Dong Y, et al. Point of care ultrasound: A WFUMB position paper. Ultrasound Med Biol 2017;43:49-58.

5. Domínguez PB. Bridging the Gap between Surgical and Conservative Treatment. The SUBA Protocol (Sports, Ultrasound, Biologics, Arthroscopy). TOBI (The Orthobiologic Institute) Conference; 2021.

6. Goto K, Saku I. Ultrasound-guided arthroscopic communication enlargement surgery may be an ideal treatment option for popliteal cysts indications and technique. J Exp Orthop 2020;7:93.

7. Rojo-Manaute JM, Capa-Grasa A, Chana-Rodríguez F, Perez-Mañanes R, Rodriguez-Maruri G, Sanz-Ruiz P, et al. Ultra-minimally invasive ultrasound-guided carpal tunnel release: A randomized clinical trial. J Ultrasound Med 2016;35:1149-57.

8. Buncke G, McCormack B, Bodor M. Ultrasound-guided carpal tunnel release using the manos CTR system. Microsurgery 2013;33:362-6.

9. de la Fuente J, Miguel-Perez MI, Balius R, Guerrero V, Michaud J, Bong D. Minimally invasive ultrasound-guided carpal tunnel release: A cadaver study. J Clin Ultrasound 2013;41:101-7.

10. Lecoq B, Hanouz N, Vielpeau C, Marcelli C. Ultrasound-guided percutaneous surgery for carpal tunnel syndrome: A cadaver study. Joint Bone Spine 2011;78:516-8.

11. Apard T, Candelier G. Surgical ultrasound-guided carpal tunnel release. Hand Surg Rehabil 2017;36:333-7.

12. Smith J, Rizzo M, Lai JK. Sonographically guided percutaneous first annular pulley release: Cadaveric safety study of needle and knife techniques. J Ultrasound Med 2010;29:1531-42.

13. Yamamoto M, Kurimoto S, Okui N, Tatebe M, Shinohara T, Hirata H. Sonography-guided arthroscopy for wrist ganglion. J Hand Surg Am 2012;37:1411-5.

14. Peck E, Ely E. Successful treatment of de Quervain tenosynovitis with ultrasound-guided percutaneous needle tenotomy and platelet-rich plasma injection: A case presentation. PM R 2013;5:438-41.

15. Sakellariou VI, Brault J, Rizzo M. Ultrasound-assisted percutaneous needle fasciotomy for Dupuytren's contracture. Orthopedics 2015;38:299-303.

16. Willberg L, Sunding K, Forssblad M, Alfredson H. Ultrasound- and Doppler-guided arthroscopic shaving to treat Jumper's knee: A technical note. Knee Surg Sports Traumatol Arthrosc 2007;15:1400-3.

17. Sunding K, Willberg L, Werner S, Alfredson H, Forssblad M, Fahlström M. Sclerosing injections and ultrasound-guided arthroscopic shaving for patellar tendinopathy: good clinical results and decreased tendon thickness after surgery-a medium-term follow-up study. Knee Surg Sports Traumatol Arthrosc 2015;23:2259-68.

18. Alfredson H. Ultrasound and Doppler-guided mini-surgery to treat midportion Achilles tendinosis: Results of a large material and a randomised study comparing two scraping techniques. Br J Sports Med 2011;45:407-10.

19. Alfredson H, Ohberg L, Zeisig E, Lorentzon R. Treatment of midportion Achilles tendinosis: Similar clinical results with US and CD-guided surgery outside the tendon and sclerosing polidocanol injections. Knee Surg Sports Traumatol Arthrosc 2007;15:1504-9.

20. Nasr P, Berman L, Rehm A. Ultrasonographic findings after Achilles tenotomy during ponseti treatment for clubfeet: Is ultrasound a reliable tool to assess tendon healing? J Child Orthop 2014;8:405-11.

21. Giannetti S, Patricola AA, Stancati A, Santucci A. Intraoperative ultrasound assistance for percutaneous repair of the acute Achilles tendon rupture. Orthopedics 2014;37:820-4.

22. Bisaccia M, Rinonapoli G, Meccariello L, Bisaccia O, Ceccarini P, Rollo G, et al. Validity and reliability of mini-invasive surgery assisted by ultrasound in achilles tendon rupture. Acta Inform Med 2019;27:40-4.

23. Severyns M, Andriamananaivo T, Rollet ME, Kajetanek C, Lopes R, Renard G, et al. Acute achilles tendon rupture: Ultrasonography and endoscopy-assisted percutaneous repair. Arthrosc Tech 2019;8:e489-93.

24. Lacoste S, Féron JM, Cherrier B. Percutaneous Tenolig(®) repair under intra-operative ultrasonography guidance in acute Achilles tendon rupture. Orthop Traumatol Surg Res 2014;100:925-30.

25. Debrule MB. Ultrasound-guided weil percutaneous plantar fasciotomy. J Am Podiatr Med Assoc 2010;100:146-8.

26. Yoo SH, Cha JG, Lee BR. Ultrasound-guided percutaneous bone drilling for the treatment of lateral epicondylitis. Eur Radiol 2018;28:390-7.

27. Koh JS, Mohan PC, Howe TS, Lee BP, Chia SL, et al. Fasciotomy and surgical tenotomy for recalcitrant lateral elbow tendinopathy: Early clinical experience with a novel device for minimally invasive percutaneous microresection. Am J Sports Med 2013;41:636-44.

28. Barnes DE, Beckley JM, Smith J. Percutaneous ultrasonic tenotomy for chronic elbow tendinosis: A prospective study. J Shoulder Elbow Surg 2015;24:67-73.

29. Sconfienza LM, Mauri G, Messina C, Aliprandi A, Secchi F, Sardanelli F, et al. Ultrasound-guided percutaneous tenotomy of biceps tendon: Technical feasibility on cadavers. Ultrasound Med Biol 2016;42:2513-7.

30. Hirahara AM, Andersen WJ. Ultrasound-guided percutaneous reconstruction of the anterolateral ligament: Surgical technique and case report. Am J Orthop (Belle Mead NJ) 2016;45:418-60.

31. Delforge S, Lecoq B, Hulet C, Marcelli C. Coracoacromial ligament section under ultrasonographic control: A cadaveric study on 20 cases. Orthop Traumatol Surg Res 2014;100:e167-70.

32. Balius R, Bong DA, Ardèvol J, Pedret C, Codina D, Dalmau A. Ultrasound-guided fasciotomy for anterior chronic exertional compartment syndrome of the leg. J Ultrasound Med 2016;35:823-9.

33. Villanueva M, Iborra A, Sanz-Ruiz P, Noriega C. Ultrasound-guided surgery for lateral snapping hip: A novel ultraminimally invasive surgical technique. J Orthop Surg Res 2021;16:322.

34. Pilecki Z, Pilecki G, Ciekalski J, Dzielicki J, Jakubowski W. The advantages of combining sonotopogram with indication and fixation in invasive ultrasound. J Ultrason 2012;12:299-306.

35. Talbot M, Harvey EJ, Reindl R, Martineau P, Schneider P. Ultrasound-assisted external fixation: A technique for austere environments. J R Army Med Corps 2016;162:456-9.

36. Hardman HD, Smyth TW, Semo JJ, Rowan CC, D'Ercole FJ. Ultrasound-guided regional anesthesia and standard of care. Reg Anesth Pain Med 2018;43:107.

37. Souto MT, Fantoni DT, Hamaji A, Hamaji M, Vendruscolo CP, Otsuki DA, et al. Ultrasound-guided continuous block of median and ulnar nerves in horses: Development of the technique. Vet Anaesth Analg 2020;47:405-13.

38. Jobe CM, Zuckerman LM. Ultrasound-assisted posterior knee arthroscopy: A description of the technique. J Ultrasound Med 2021;40:1949-53.

39. Pilecki, Z, Koczy B, Mielnik M, Pilecki G, Dzielicki J, Jakubowski W. Basic dissecting techniques in ultrasound-guided surgery. J Ultrason 2014;14:171-8.

40. Finnoff JT, Hall MM, Adams E, Berkoff D, Concoff AL, Dexter W, et al. American medical society for sports medicine position statement: Interventional musculoskeletal ultrasound in sports medicine. Clin J Sport Med 2015;25:6-22.

41. Dallo I, Morales M, Gobbi A. Platelets and adipose stroma combined for the treatment of the arthritic knee. Arthrosc Tech 2021;10:e2407-14.

42. Dallo I, Szwedowski D, Mobasheri A, Irlandini E, Gobbi A. A prospective study comparing leukocyte-poor platelet-rich plasma combined with hyaluronic acid and autologous microfragmented adipose tissue in patients with early knee osteoarthritis. Stem Cells Dev 2021;

43. Finnoff JT, Berkoff D, Brennan F, DiFiori J, Hall MM, Harmon K, et al. American medical society for sports medicine recommended sports ultrasound curriculum for sports medicine fellowships. Br J Sports Med 2015;49:145-50.

Conflict of Interest: NIL
Source of Support: NIL

How to Cite this Article

Pedro BD, Ignacio DL | State of the Art in Ultrasound-Guided Surgery: Concept, Planning, Instruments, Classifications, Indications, and Literature Review. | Journal of Regenerative Science | Jan - Jun 2022; 2(1): 16-21.